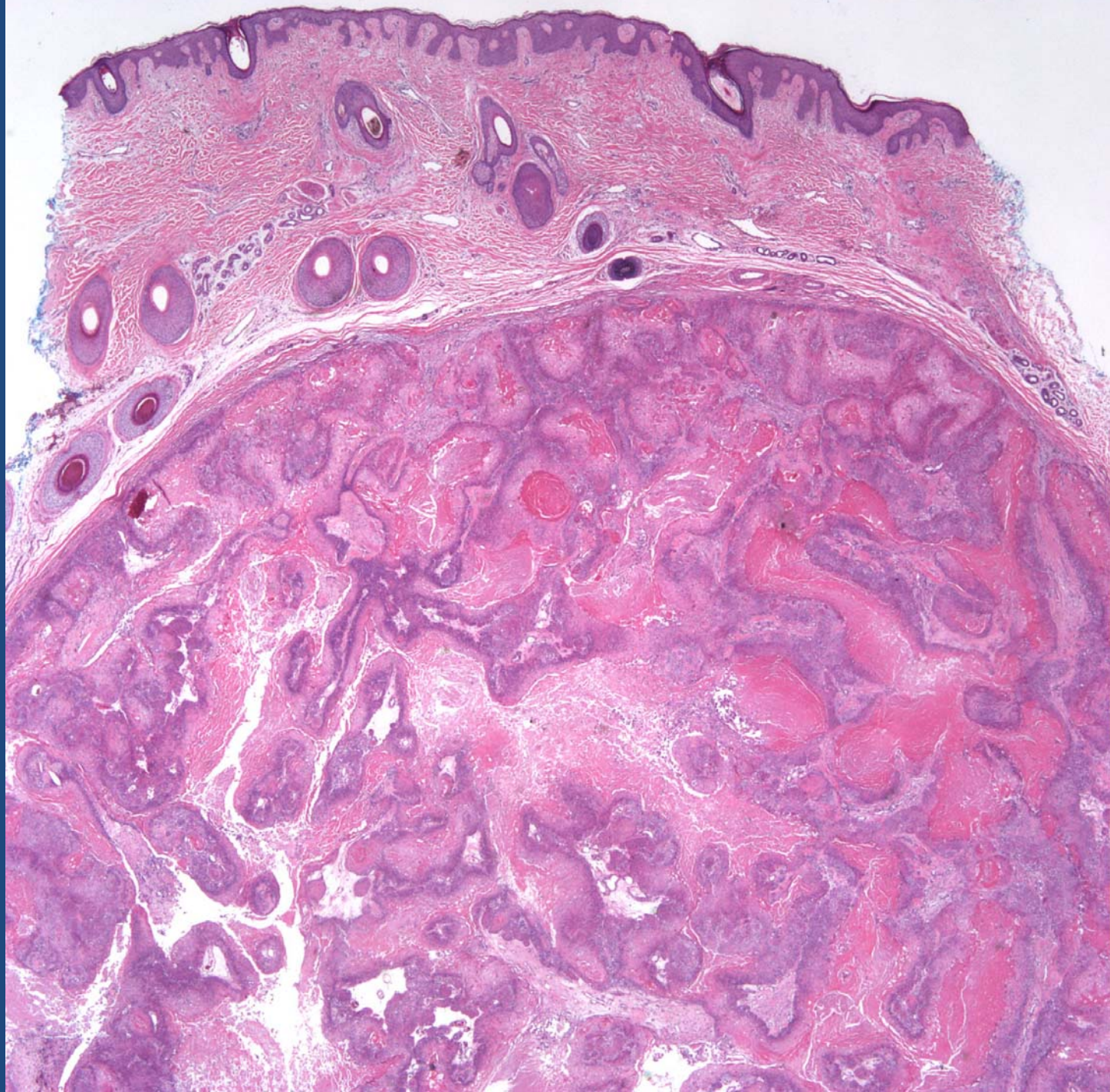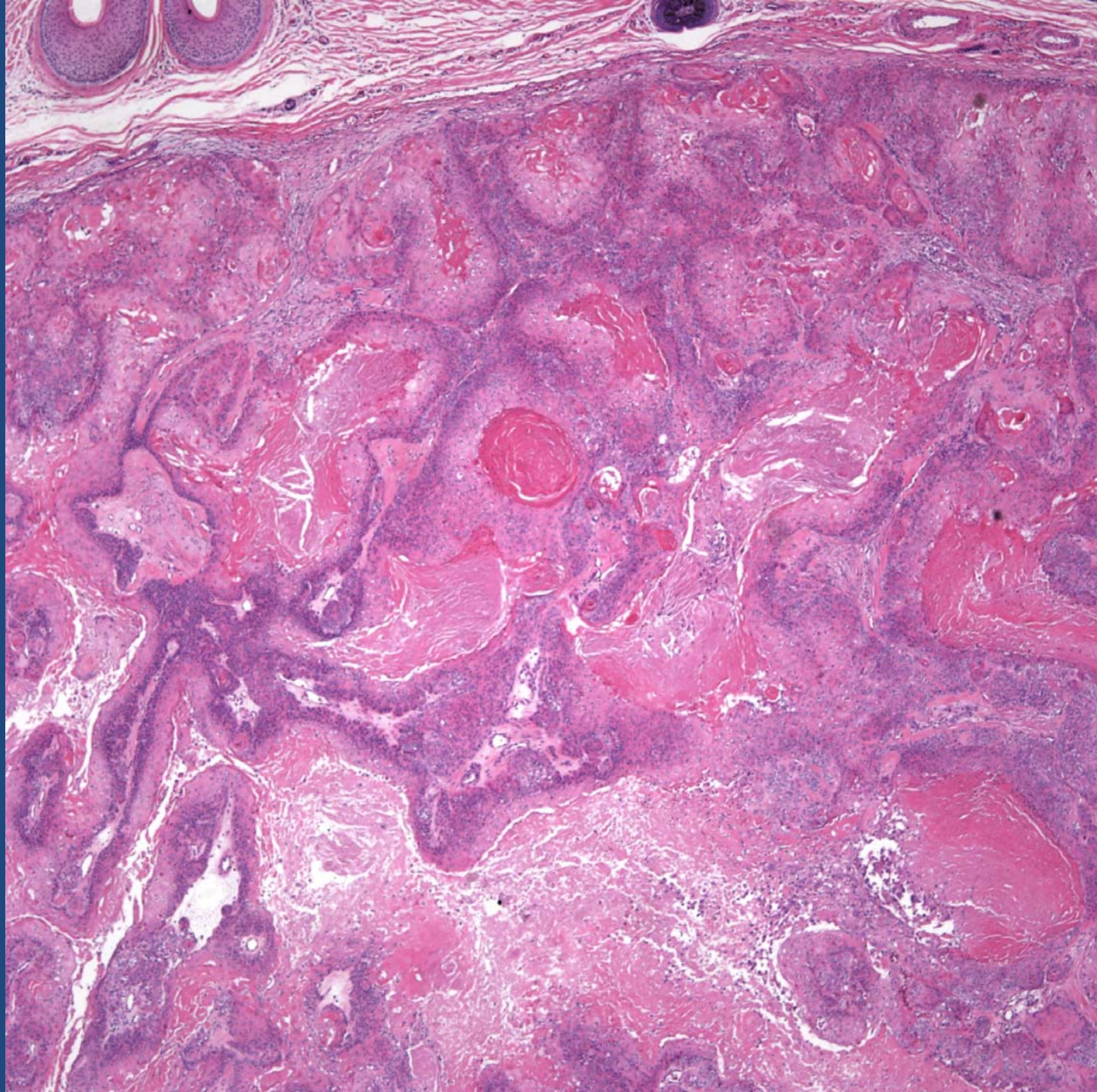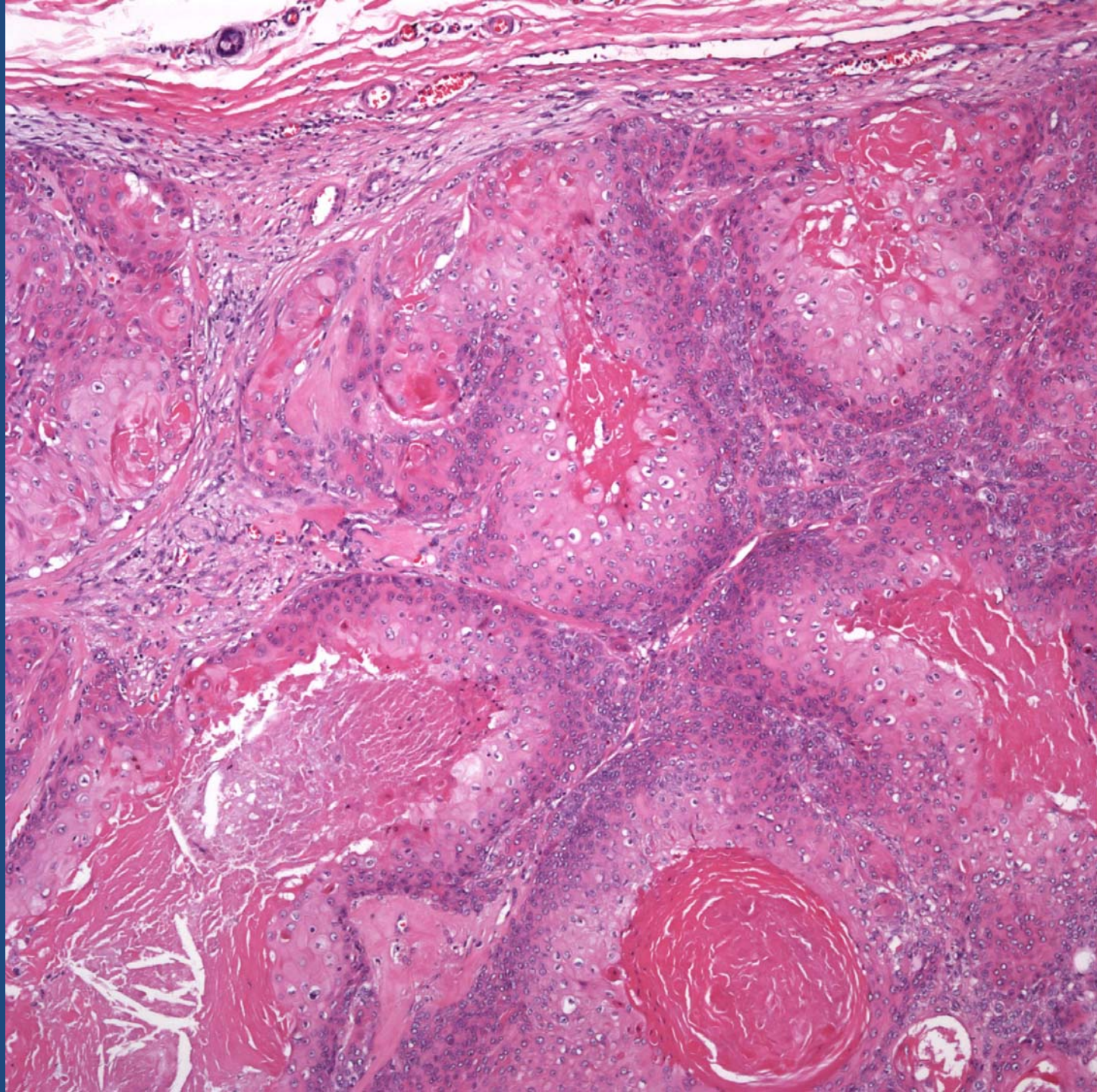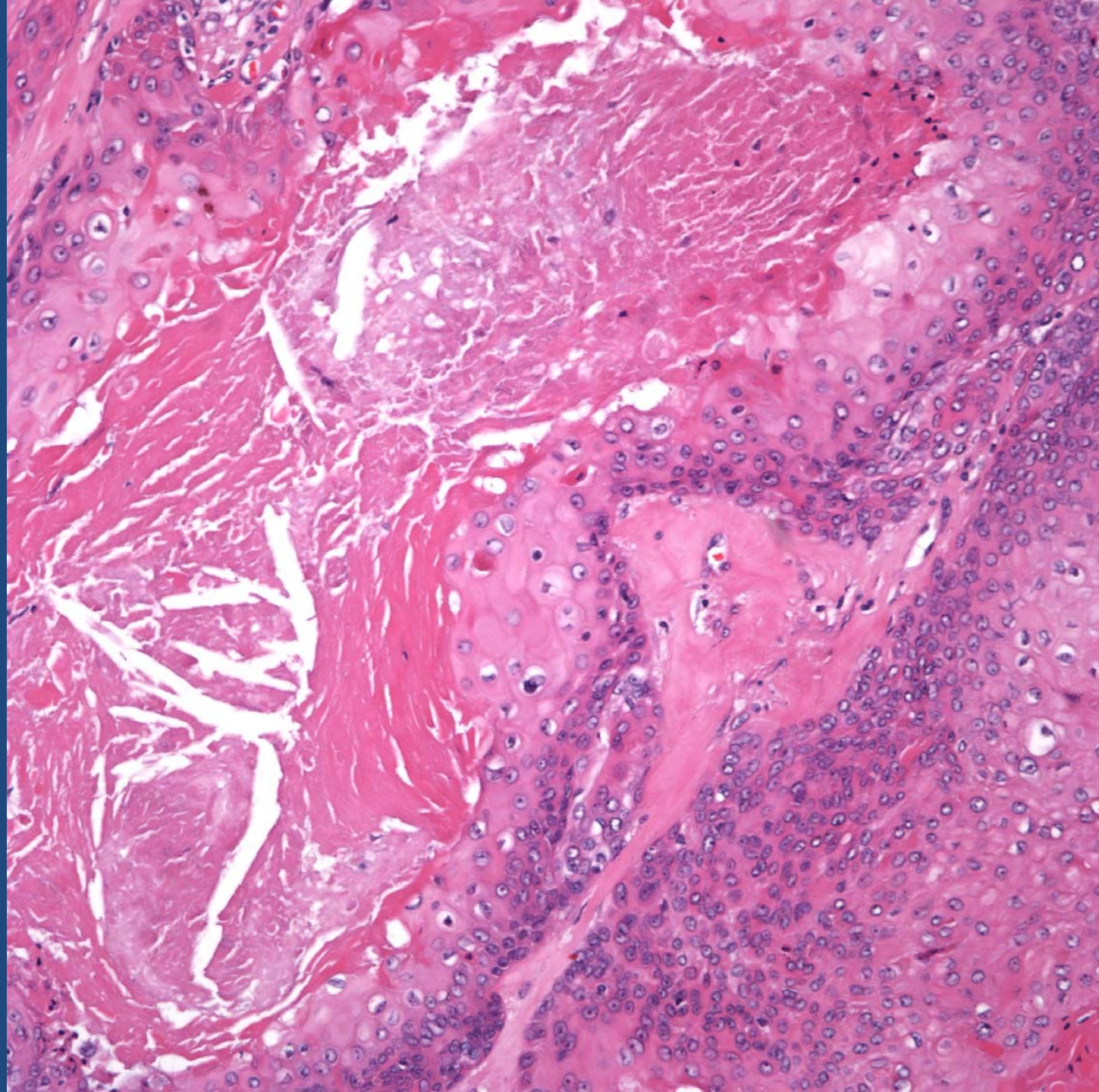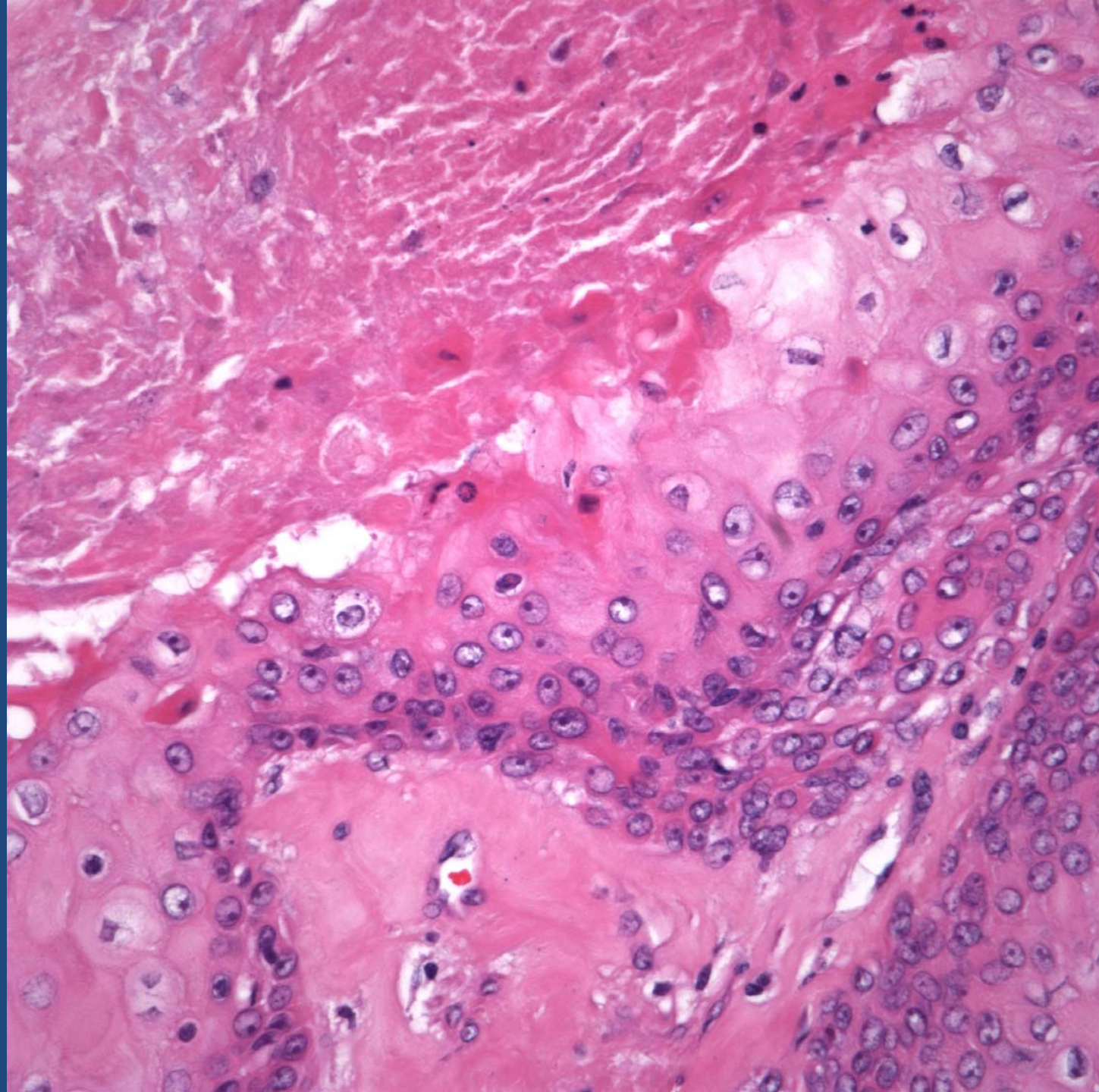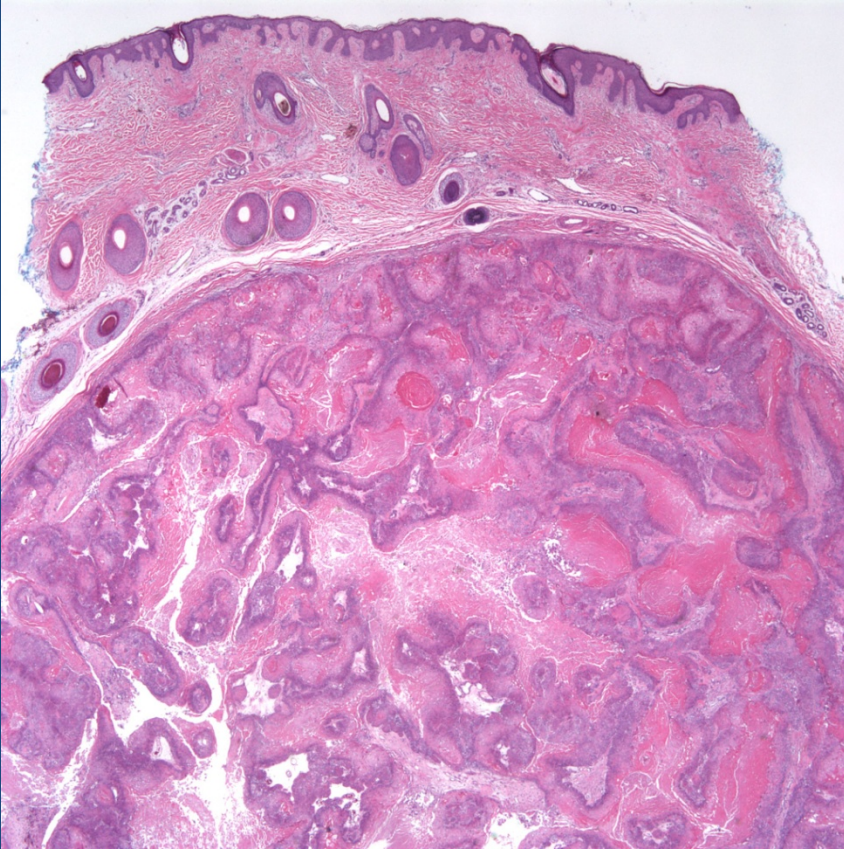


Proliferating Pilar Tumor (Proliferating Tricholemmal Cyst)

Pearls



- Well-circumscribed tumor of pilar differentiation with multiple foci of shadow cells and
- Typical areas of tricholemmal keratinization merge with areas of epidermal keratinization